

## UV MICROSCOPY

# A better understanding of the tissue degeneration

with ultraviolet light


one photon + one photon = one photon

**T**issue degenerations appear at the early stages of many pathologies. Better appreciations allow earlier diagnostics. The repartition of the fibres in the tissues can be measured using state of the art optical photonic microscopy method. The first technique consists in combining fluorescence from two-photon excitation and second harmonic generation microscopy. When two photons are focused in a femto-volume for a time lower than a picosecond, non-linear phenomena show up: the two photons can be virtually added to be absorbed by a molecule usually excited by a single photon with a double energy. Moreover, a non-linear scattering with proper selection generates a second harmonic (SHG signal). The second technique available takes profit of the deep ultraviolet range (DUV) emitted in the synchrotron radiation for fluorescence microscopy. Both techniques have been settled on the DISCO beamline at SOLEIL in order to compare the information obtained on several types of tissues.

## Rat tail and mouse liver

The rat tail tendon, rich in collagen, is a perfect example for comparing the complementarity of information obtained with the two techniques. Figure 1 shows it is possible to quickly image the fibrillar collagen, the non fibrillar one, aromatic amino-acids and the NADH and FAD.

Once tested on this kind of model, it became interesting to try to adapt the method on a first pathology. The Hepatobiliary Center of APHP (Kremlin



**Figure 1.** Tendon of a rat tail observed according several UV imaging techniques on DISCO (two-photon excitation for the upper cases, and single-photon excitation for the lower cases). Fibrillar collagen (up left), NADH and FAD (up right). Collagen, elastin and NADH (low left). Collagen and aromatic amino-acids (low right). The scale bar is 100µm.

Bicêtre), the University Paris Sud and the INSERM have prepared a degeneration tissue model in mice with a gradation of the disease, starting with a simple steatosis and progressing in a non-alcoholic fattening liver disease (NAFLD), then in a fibrosis, that may finally lead to a cirrhosis and hepatocarcinoma.

## Techniques with complementary results

The complementarity of the two techniques become obvious on figure 2, where non fibrillar collagen supporting the erythrocytes in the veins is not visible using two-photon excitation. Thanks to this one last technique, it is possible to easily image type I and II of fibrillar

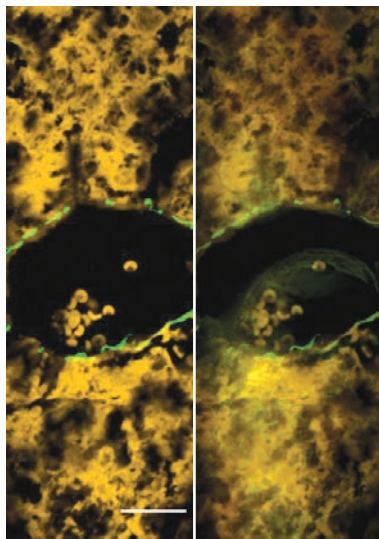


Figure 2. On the left, the UV obtained with two-photon excitation are only specific to the fibrillar collagen (in green) and do not detect the non-fibrillar observable collagen (on the right) in single-photon excitation (at the center in green).

collagen without detecting the other types of collagen. The single-photon technique in deep UV reveals all type of collagen, without any discrimination. Combining these two microscopy techniques on a single tissue area offers a better overview of all the fibrillar collagens involved in pathologies.

Figure 3 confirms that the observable collagen with SHG excitation is mainly structuring, i.e. it mainly corresponds to the tissue limits and to the frame of the veins (up of the figure). However, the observable collagen with single photon excitation is not only structuring. The amount of collagen measured in each image can thus be linked to a disease stage. An increasing development of the total collagen has been observed for mice suffering from NASH.

The results show that some types of liver collagen can be quantified using second harmonic generation microscopy (SHG). DUV microscopy is less specific than SHG, but it allows detec-

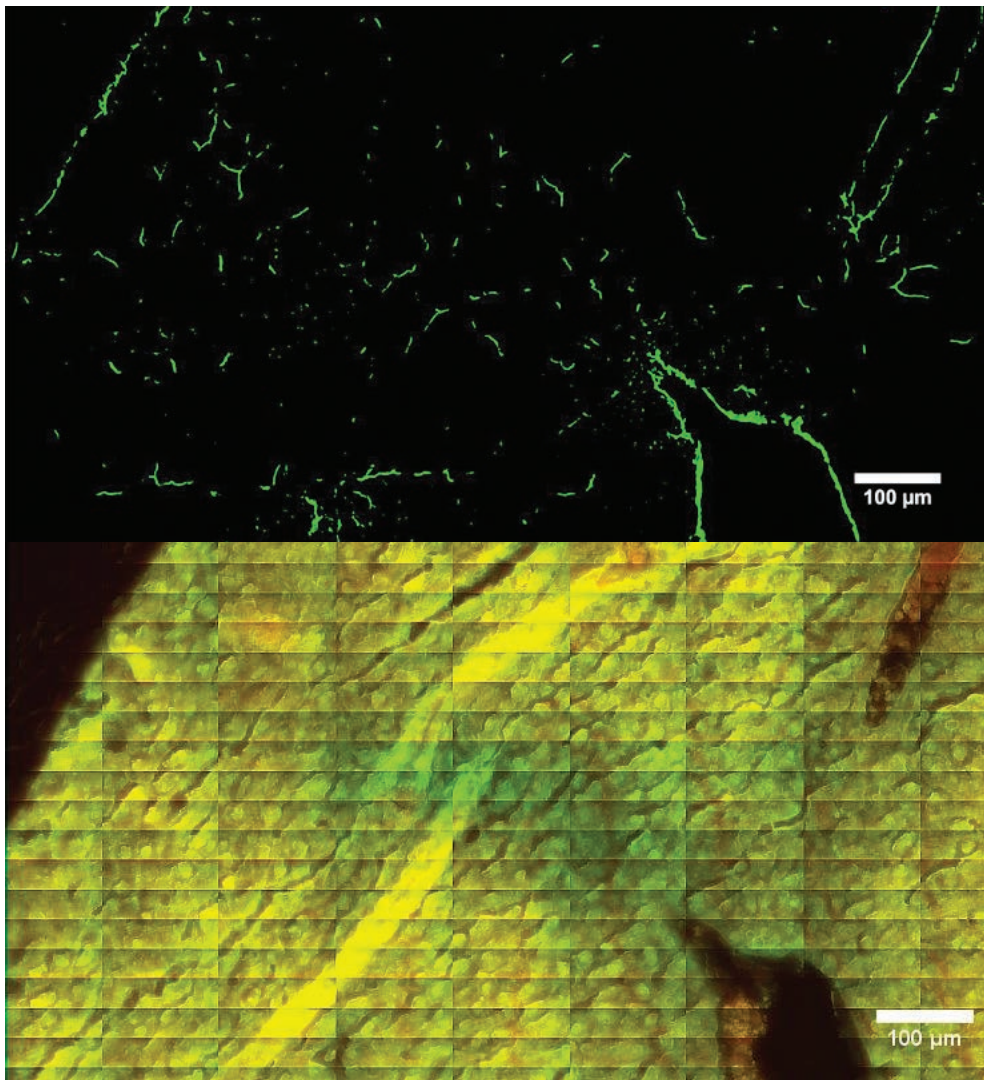


Figure 3. Mouse tissue, NASH in SHG excitation (up) and in ultraviolet single-photon excitation (low).

ting every protein and more types of collagen. It is worth noticing that according to scientists involved knowledge, this is the first use combining the three techniques for a liver histological analysis. Beyond the first results, the techniques combination may be easily used on other pathologies involving tissue degeneration.

→ **Contact:**  
[matthieu.refregiers@synchrotron-soleil.fr](mailto:matthieu.refregiers@synchrotron-soleil.fr)

Reference:  
**Zubkovs, V. et al.**  
 Analyst, 139(11): 2663 (2014).